

LARGE EXTREMITY TUMORS RESULTING IN DIFFICULT CLOSURE

Joseph C. Glennon, VMD, Diplomate ACVS

Surgeon – Veterinary Specialty Referral Center, Adjunct Associate Professor of Surgery – Albany Medical College

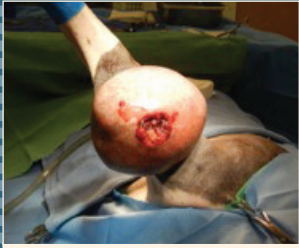

Figure 1: Large ulcerated neoplasia located at the flexor surface of the right elbow joint.

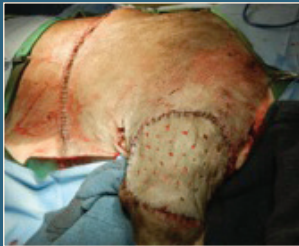

Figure 2: Full-thickness mesh graft used to close a large skin defect.

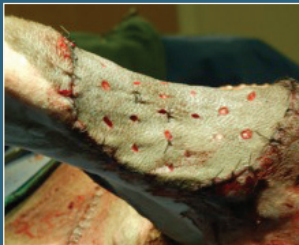

Figure 3: Several sutures are placed at strategic locations to anchor it to the recipient bed.

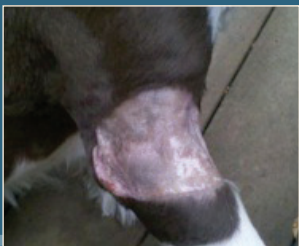


Figure 4: Full-thickness mesh graft one month post-op. Hair is starting to grow in the graft.

Introduction

Not only are large tumors involving the extremities difficult to excise, the resulting larger skin defect poses a real challenge to close. Familiarity with various options and careful surgical planning can make a big difference between amputation and limb preservation.

Patient Information

“Zoe” is an 11 year-old, 23.6 kg, female spayed English Springer Spaniel who presented to VSRC for a large (12.7 x 9.2 x 7.2 cm), ulcerated mass located on her right forelimb at the flexor surface of the elbow joint (Figure 1). The mass had been growing for over one year, and just prior to presentation, it began to ulcerate and was causing lameness.

Physical exam revealed a large, hairless, broad-based lesion, extending $\frac{3}{4}$ around the limb, involving the cranial, craniomedial, and lateral margins surfaces of the elbow joint. The mass was limiting flexion of the elbow joint. The remainder of her physical exam was normal and no co-morbidities were identified. Cytological exam revealed large mononuclear cells with occasional small lymphocytes and rare non-degenerative neutrophils, consistent with mild chronic inflammation.

Surgery

Pre-anesthetic blood evaluation and three-view thoracic radiographs were normal. Images of the right elbow did not reveal any osseous involvement. Pre-surgical planning for wound closure involved either a full-thickness mesh graft or axial pattern flap based on the thoracodorsal artery and vein. The affected limb and potential donor sites were prepared for surgery. The mass was excised along with a 2 cm wide peripheral margin of normal tissue and as deep a margin as permissible. An isthmus of normal skin (approximately 3 cm width) was left along the medial surface, which helps minimize lymphatic edema in the distal extremity. The resulting skin defect was approximately 14.0 x 11.0 x 2.0 cm.

A full-thickness mesh graft was chosen over a thoracodorsal based axial pattern flap because of utility, conformity, and ease of harvesting and application. A section of full thickness skin with dimensions slightly larger than the skin defect at the tumor site was harvested from the ipsilateral, lateral thoraco-abdominal region. The graft was prepared by removing the underlying fat to the level of the hair follicles. Multiple small staggered fenestrations parallel to the lines of tension were made in the graft. Meshing allows for drainage, which minimizes lifting of the graft off the recipient bed, helps with expansion, conformity, and adherence to irregular surfaces. Small gauge monofilament sutures (4-0/5-0 nylon) are placed around the periphery of the graft (Figure 2). A few “anchoring” sutures can also be placed at strategic points (concave or convex surfaces) in the middle of the graft. Care is taken to avoiding any tension across the graft surface and at the graft-recipient skin interface. After the graft is anchored in place, the donor site is closed primarily (Figure 3).

Aftercare

Maintaining sterile technique, the graft is covered with a sterile non-adherent pad coated with a thin layer of antibiotic ointment. This primary layer helps retain moisture, promoting epithelialization and preventing dehydration. The secondary intermediate layer, absorbable bandage material is also sterile. A splint is incorporated into the tertiary layer because movement of the graft interferes with revascularization. The first bandage change takes place 4-5 days after the procedure. During this time the graft becomes viable through two processes, plasmatic imbibition and vascular inosculation. Plasmatic imbibition is the “drinking” of plasma, erythrocytes, and polymorphonuclear cells from the recipient bed via capillary action. Vascular inosculation is the budding and anastomosis of vessels from the recipient bed into the graft. When changing the bandage, the patient is usually sedated and care is taken to prevent dislodging the graft from the recipient site. A healthy viable graft should have a contused (port wine) appearance, due to the absorption of hemoglobin products and sluggish blood flow in the graft. Unhealthy grafts have a white or black appearance. If areas of the graft have questionable viability, they are left in place until they further define themselves. The bandage and splint are replaced, again using sterile dressing, and it is changed in another 4-5 days. Sutures are removed in 10-14 days and the limb re-banded for an additional 10-14 days. In most cases, the granulation tissue that grows into the graft fenestrations will be completely epithelialized and the graft will be mature enough to discontinue bandaging after approximately 4-6 weeks. Hair will continue to grow from the graft’s follicles so always try to place the graft in alignment with the surrounding hair direction to maximize cosmetic appearance.

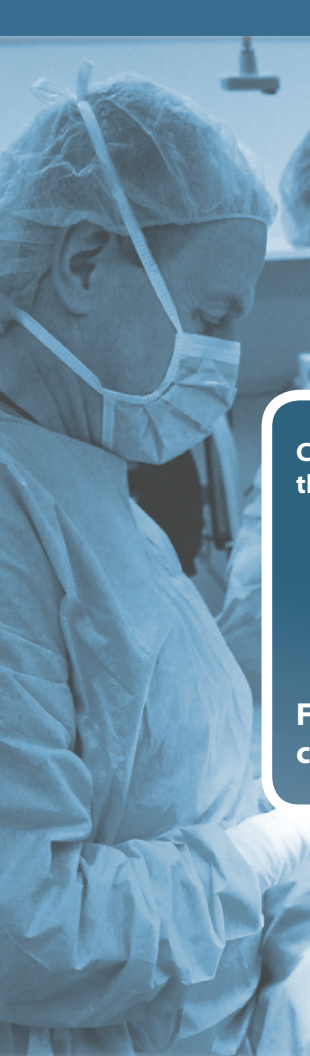Summary

Full-thickness mesh grafts offer much utility when closing a large surgical defect on an extremity. They are versatile, robust, and, when managed correctly, can result in 90-100% “take” (Figure 4).

This tumor was histologically characterized as a nerve sheath tumor with a low mitotic index, absent vascular invasion, and completely excised. Given its biological behavior, there is a very low risk of metastasis however recurrence is likely.

“Zoe” is no longer carrying a 1.8 kg tumor burden, she has normal range of motion in her elbow joint, her lameness has resolved, and she is enjoying all of her normal summer activities including swimming (Figure 5).





1641 Main Street • Pattersonville, NY 12137

Caring for surgical patients from three locations:

- **Pattersonville** – Main Location
- **Gansevoort** – 35 Fawn Road (at Northway Animal ER Clinic)
- **Latham** – 223 Maxwell Road

For all appointments please call: 518.887.2260



VMD: University of Pennsylvania
Internship: The Animal Medical Center
Residency: Cornell University
 Adjunct Associate Professor of Surgery, Albany Medical College
 National Institute of Health (NIH) Grant Co-Investigator

Joseph C. Glennon, VMD, Diplomate ACVS – Founder of VSRC

YOUR SURGICAL PARTNERS

Minimally Invasive • Neurologic • Oncologic • Orthopedic • Reconstructive • Soft Tissue



DVM: University of Florida
Internship: Colorado State University
Residency: Cornell University



Courtney Fitzpatrick, DVM, Diplomate ACVS

PLEASE LET US KNOW IF YOU WOULD LIKE TO BE LISTED AS A REFERRING PARTNER ON OUR WEBSITE.

Summer 2013 – Issue No. 1

IN THIS ISSUE

Large Extremity Tumors Resulting in Difficult Closure

Your Surgical Partners

VETERINARYSPECIALTIES.COM